

# Little League Shoulder

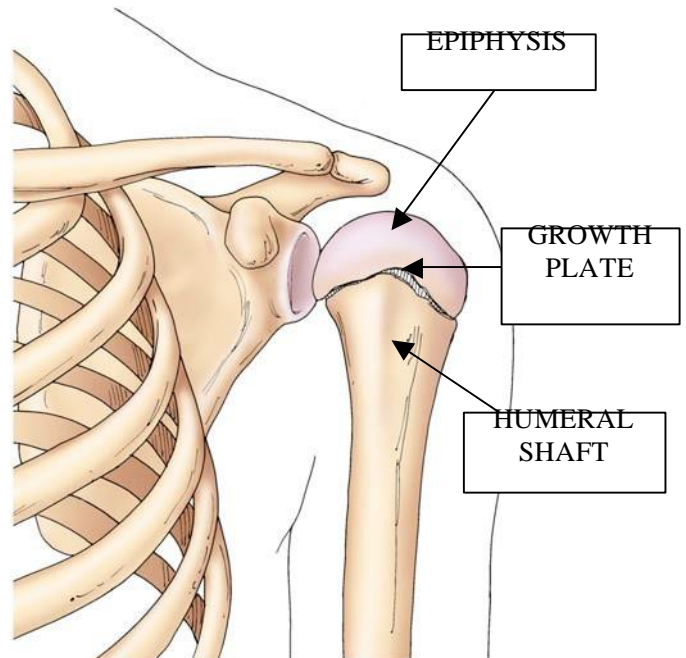
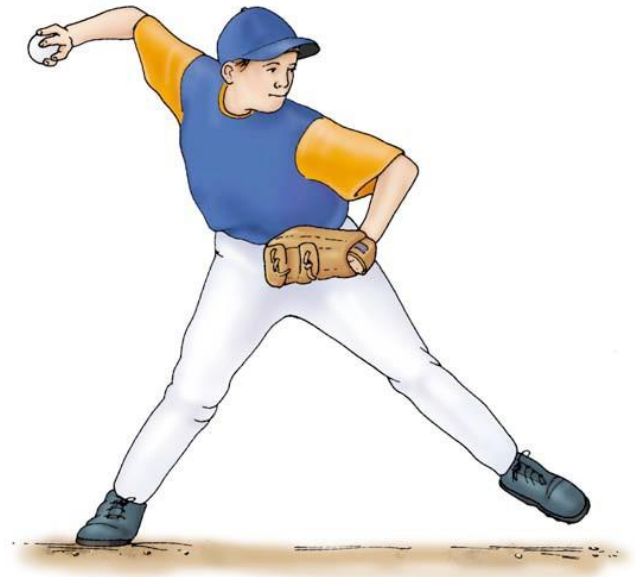## Proximal Humeral Epiphyseolysis

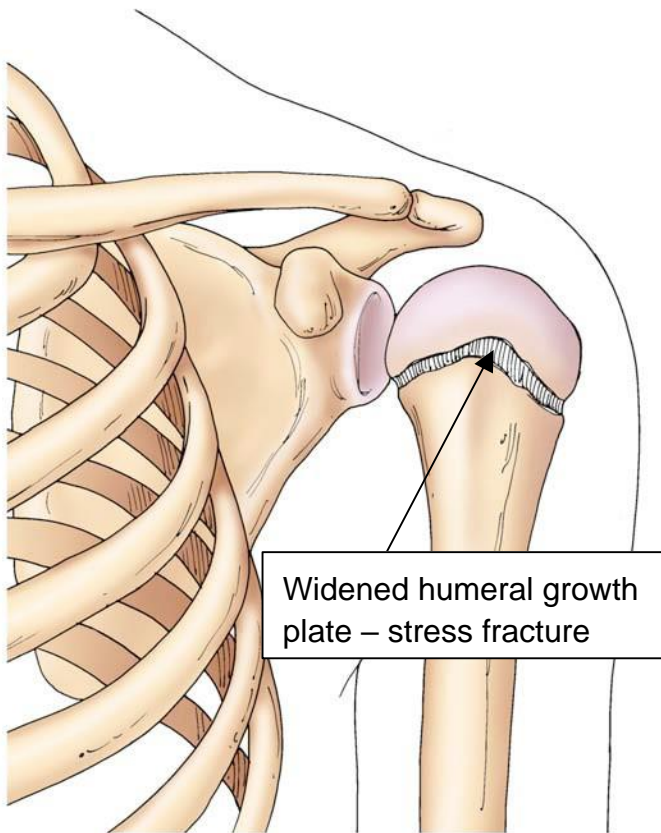
Little League shoulder is an overuse injury commonly seen in pitchers, gymnasts, and tennis players usually from ten to fifteen years of age with open growth plates. The condition begins as a vague shoulder pain that worsens with stressful use of the arm during or after a game or an intensive practice program.

The injury to the growth plate is the result of the extreme rotatory torque that occurs with the repetitive, overhead movement of the shoulder followed by a rapid deceleration common to these sports activities.

Current literature suggests that for baseball, pitching is limited to three to four innings per game or ninety pitches per game, and less than two hundred pitches per week. However, parents and coaches often fail to include the number of repetitive “practice” movements that are typical for devoted trainees, whether they are pitchers, gymnasts, or tennis players. training. It is the cumulative number of overhead

maneuvers over days or weeks that can lead to injury of the proximal humeral growth plate.





If treatment is sought at the onset of pain, the physical examination will demonstrate tenderness around the upper arm and some loss of flexibility. The differential diagnosis includes tumors of the upper arm, painful impingement arc, and rotator cuff injury. X-rays at this stage are often interpreted as normal. Immediate restriction of these activities can prevent the patient from entering the next stage – stress fracture of the proximal humeral growth plate. With this stage, the pain does not appear to resolve with rest and a decrease in the child's sports skill level is reported. Physical

examination may demonstrate loss of range of motion and global muscle weakness. The tell-tale signs of the diagnosis can now be confirmed on x-ray with widening of the growth plate due to the repetitive stress fractures that have not been given a chance to heal properly. In extreme cases, the growth plate will completely fracture into two pieces. The treatment of a chronic stress fracture or proximal humeral epiphysiolysis, is three to six months of rest, increased Vitamin D intake, and elimination of extreme overhead sports activity. Once the growth plate is normal on x-ray, the pediatric orthopedic surgeon will prescribe a regimen of truncal core muscle conditioning and isometric upper extremity muscle conditioning to decrease the likelihood of this condition recurring. Once the growth plates have closed with the onset of hormones and adolescent growth spurt, this condition cannot occur.



©John T. Killian, M.D. & Sharon Mayberry, M.D.